The Versatile Helium Balloon Mastopexy

Edward A. Pechter, MD; and Shanell Roberts, ORT

BACKGROUND: Mastopexy is a challenging procedure, particularly with the trend toward procedures with lesser scarring. When combined with breast augmentation, the risk of complications is greater than with either component alone.

OBJECTIVE: An attempt was made to simplify mastopexy, giving a "what you see is what you get" result before any surgical bridges are crossed while minimizing disruption of the breast gland and its circulation.

METHODS: A variation of the L-shaped mastopexy technique was developed that uses tailor-tacking to delineate the amount and pattern of skin resection necessary to give the breast the desired shape. An oblique skin resection in the lower, outer quadrant of the breast provides a good environment for healing while allowing tightening of the skin brassiere in the vertical and horizontal planes. Skin undermining and pedicle formation are eliminated, as is reliance on a circumareolar suture. The procedure is called the "helium balloon" technique for the allusion to the ascent of the breasts as well as the configuration of the closed incisions.

RESULTS: Seventy-two patients underwent mastopexy or augmentation/mastopexy over a period of 3 years with good results and an acceptable rate of revisions and complications. The technique has recently been extended to mastopexy after lipoplasty breast reduction in 2 patients.

CONCLUSIONS: Mastopexy and augmentation/mastopexy can be performed with predictably good results and minimal risk of serious complication by following the principles outlined for the "helium balloon" technique.
(*Aesthetic Surg J 2008;28:272–278*)

Ptosis is said to exist when the breast mound and/or the nipple-areola complex descend on the chest wall due to diminished tissue elasticity secondary to aging, pregnancy, weight fluctuation, or other factors. No single technique has been found to satisfactorily correct all degrees of ptosis but the trend has been toward "short scar" mastopexy. Rohrich and colleagues[1] categorized 4 variations of short scar mastopexy: the periareolar, the inverted-T, the L-shaped scar, and the vertical. The periareolar technique limits the scar to the border of the areola but anything more than a minimal lift with this method may yield a truncated breast and/or stretched areola. Inverted-T techniques involve horizontal scars in the inframammary fold that are prone to hypertrophy, especially medially. Wound healing problems at the T-junction of the vertical incision with the inframammary fold incision are another drawback to these procedures. L-scar techniques generally eliminate the medial component of the horizontal inframammary scar.[2-9] Some of the L-scar techniques involve complex markings and technical instructions that demand considerable surgical experience.

Dr. Pechter is Assistant Clinical Professor, Division of Plastic Surgery, University of California, Los Angeles, CA and in private practice in Valencia, CA. Ms. Roberts is an operating room technician in Dr. Pechter's Valencia office.

Vertical scar techniques add a vertical limb to the periareolar scar. It is generally accepted that the vertical component of the scar should not cross the inframammary fold (IMF), since scars on the chest wall may be visible or hypertrophic. Dealing with the excess lower pole skin in the limited area between the 6 o'clock position of the areola and the inframammary fold can be problematic, necessitating gathering of the skin in purse-string fashion or other maneuvers. The evolution of the vertical reduction mastopexy was chronicled by Spear and Howard,[10] who commented that, "Although avoiding a transverse scar pattern is the goal of a vertical reduction pattern, a short, tidy transverse scar may be equally or more desirable than a purely vertical scar with irregularities."

Use of an oblique incision is not new, representing modifications of a procedure described by Strombeck[11] in 1960, but these techniques usually add a scar in at least a portion of the IMF. The helium balloon (HB) lift most closely resembles a technique described by Dufourmentel and Mouly[12] in the French literature although, unlike that technique, the oblique scar is not extended onto the chest wall. Additionally, the HB technique avoids any skin undermining or parenchymal reshaping. thus minimizing the risk of ischemic complications and fat necrosis. Also, the lower pole incision in the HB technique originates at the 6 o'clock position of the areola, which assists in the vertical elevation of the

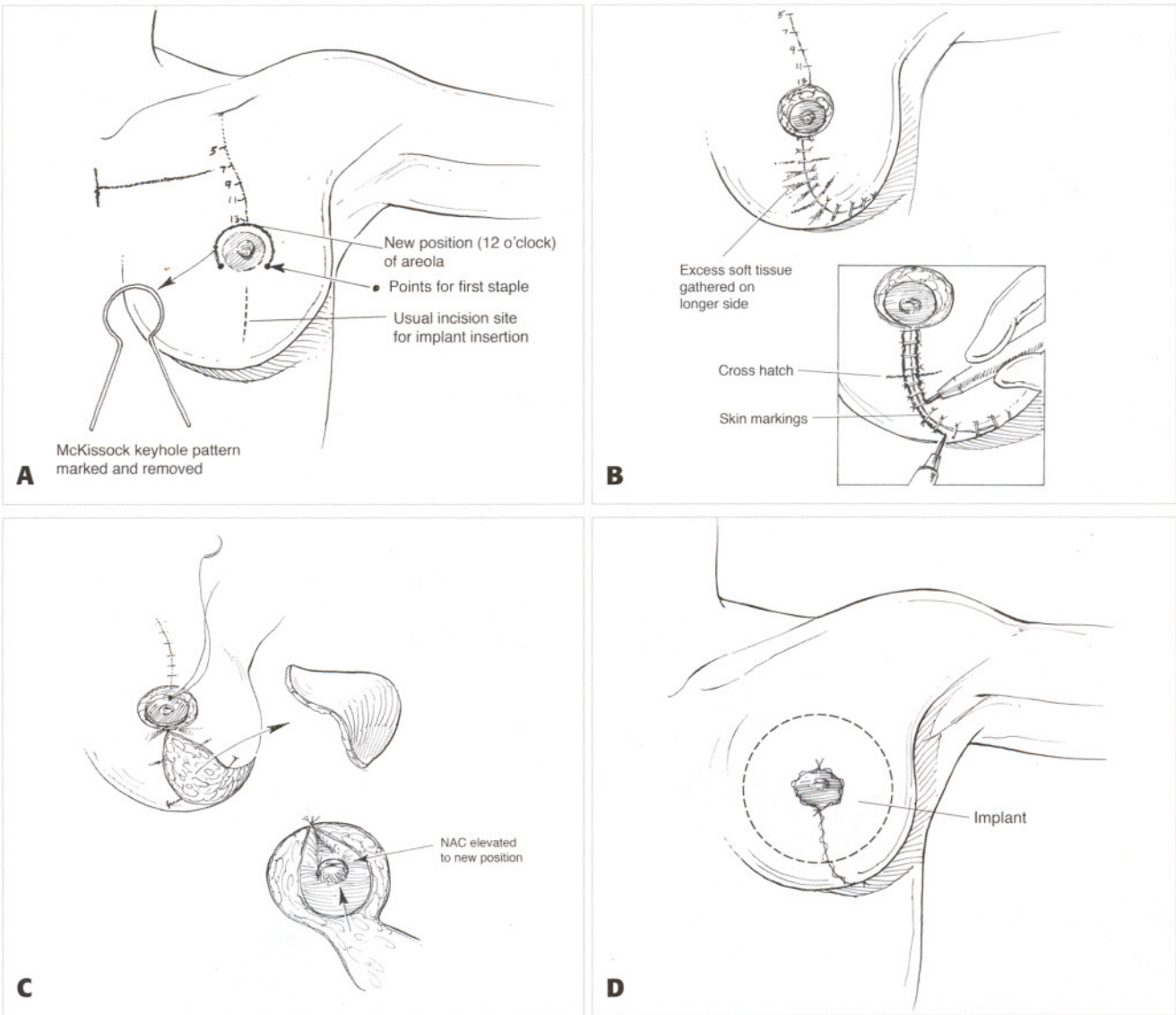

Figure 1. A-D, Schematic illustration of helium balloon mastopexy. **A,** Demarcation of meridian line and areola location. **B,** Serial placement of staples. **C,** Skin excision and elevation of NAC. **D,** Implant placement.

nipple, rather than at the 4 o'clock position (left breast) or 8 o'clock position (right breast) described by the French authors, which may push the nipple excessively medial or give the breast an oblong shape.

The helium balloon lift is particularly well-suited for the difficult combination of augmentation and simultaneous mastopexy.[13-18] Spear[13] observed that the risk of the combined procedures is greater than the sum of the risk of the individual components, mentioning increased chances of infection, implant exposure, loss of nipple sensation, nipple or implant malposition, nipple or skin necrosis, and objectionable scarring. He explained that these risks are present because of the conflicting goals of augmentation and mastopexy, with augmentation stretching the skin envelope and mastopexy tightening it. Haeck,[14] in commenting on medico-legal issues of augmentation/mastopexy, noted that the final result may be unpredictable in even the best of hands.

The concept of the helium balloon lift is that some limitations of the vertical scar procedures can be mitigated by rotating and extending the scar to the lower, outer quadrant of the breast while eliminating the potentially troublesome medial inframammary limb and T-junction of the inverted-T mastopexy. Because the appearance of the breast is prefigured by placement of surgical staples,[19] the result is more predictable, and since it is not necessary to undermine skin or create a pedicle to carry the nipple/areola, ischemic risks are diminished.

PATIENTS AND METHODS

Patients

All patients selected for mastopexy or mastopexy/augmentation with the helium balloon technique had either Grade II (moderate) or Grade III (severe) ptosis according to Regnault's classification,[20] meaning that the nipples were below the level of the inframammary fold and either above (Grade II) or at (Grade III) the lower contour of the gland. Among 22 patients treated, patient ages ranged from 18 to 66 years; the average age was 41.

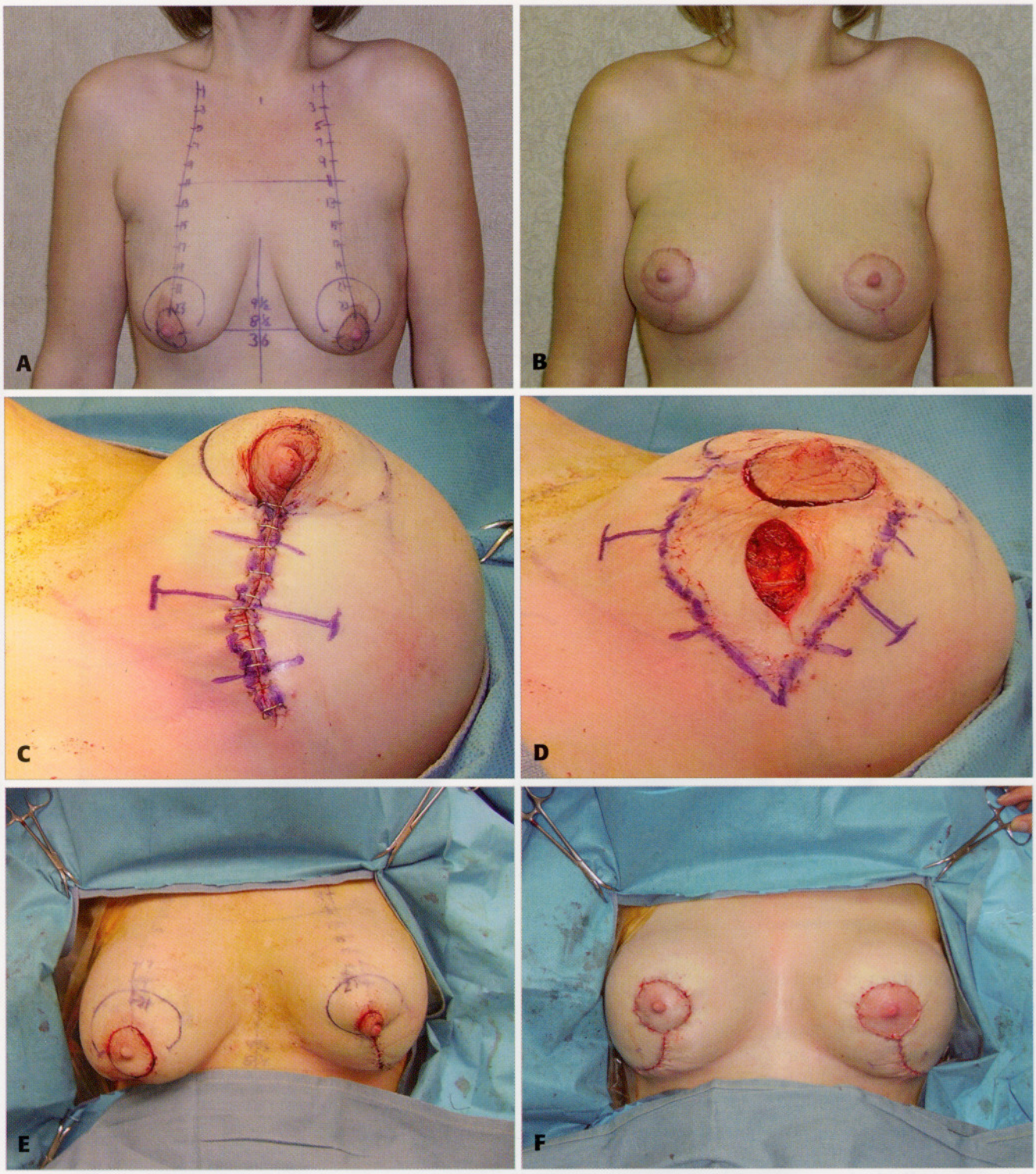

Figure 2. A, Preoperative view of a 31-year-old patient with severe ptosis following 135-pound weight loss. **B,** Postoperative view 1 month after surgery. **C,** Left breast stapled after placement of 300-cc saline-filled implant with patient supine. **D,** Outline of left breast skin resection (patient supine). **E,** Intraoperative view of patient in sitting position after stapling of left breast. **F,** Intraoperative view of patient in sitting position after suturing of both breasts. The "helium balloon" pattern of incisions is evident.

Technique

The standing patient was marked preoperatively. A breast meridian line was drawn from each mid-clavicle to the corresponding nipple with matching 2-cm intervals marked on each line, symmetrical placement guided by the use of a carpenter's level. An areola of the desired diameter was marked around the nipple. The appropriate new location of the nipple was determined by the surgeon's preferred method, generally placing it on the anterior aspect of the breast at the projection of the IMF. The numbered intervals were useful for maximizing symmetry, especially if intraoperative adjustments to the

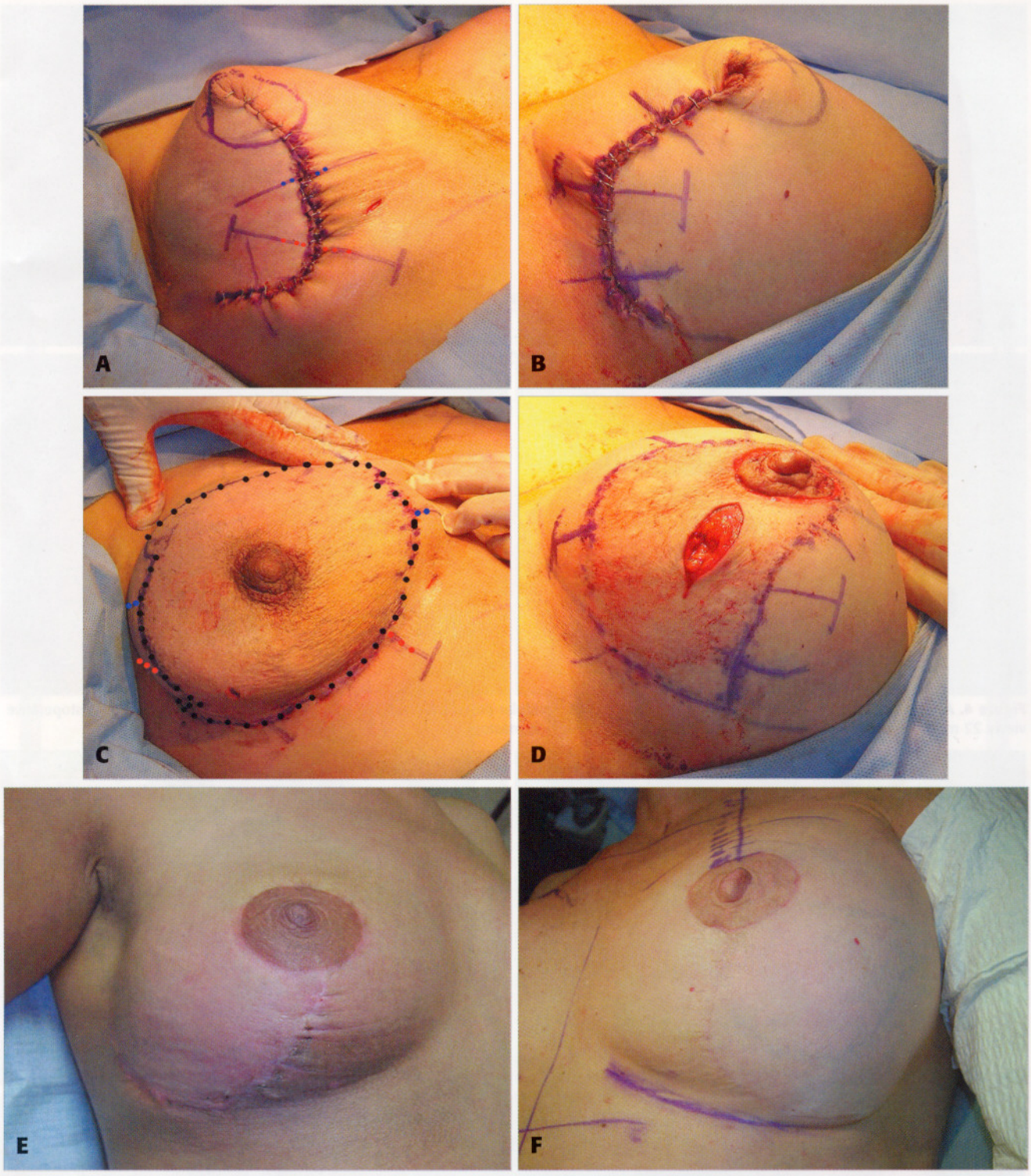

Figure 3. A, C, E Right breast of a patient undergoing a a large amount of skin resection. **A,** Intraoperative appearance of stapled breast. **C,** Outline of skin to be resected. **E,** Location of scar 3 months postoperatively. Pre- and postoperative views of the patient are shown in Figure 6. **B, D, F,** Left breast of patient similar to patient at left but undergoing augmentation and an average amount of skin resection. **B,** Intraoperative appearance of stapled breast. **D,** Outline of skin to be resected. **F,** Location of scar 2 months postoperatively.

planned nipple position proved necessary. A wire pattern (McKissock Keyhole Pattern; Padgett Instruments, Kansas City MO) was used to mark the new areolar window, removing excess areolar pigmentation if at all possible.

The patient was positioned supine on the operating table and anesthetized. If a mastopexy only was to be performed, the first surgical staple was placed to approximate the ends of the new areolar window (Figures 1 and 2). Gathering redundant lower pole skin between forceps, additional staples were serially placed from the first staple (the new 6 o'clock position of the areola) vertically downward toward the IMF. As the stapled closure approached the IMF it was curved laterally toward the lower, outer quadrant of the breast. If there was a discrepancy of

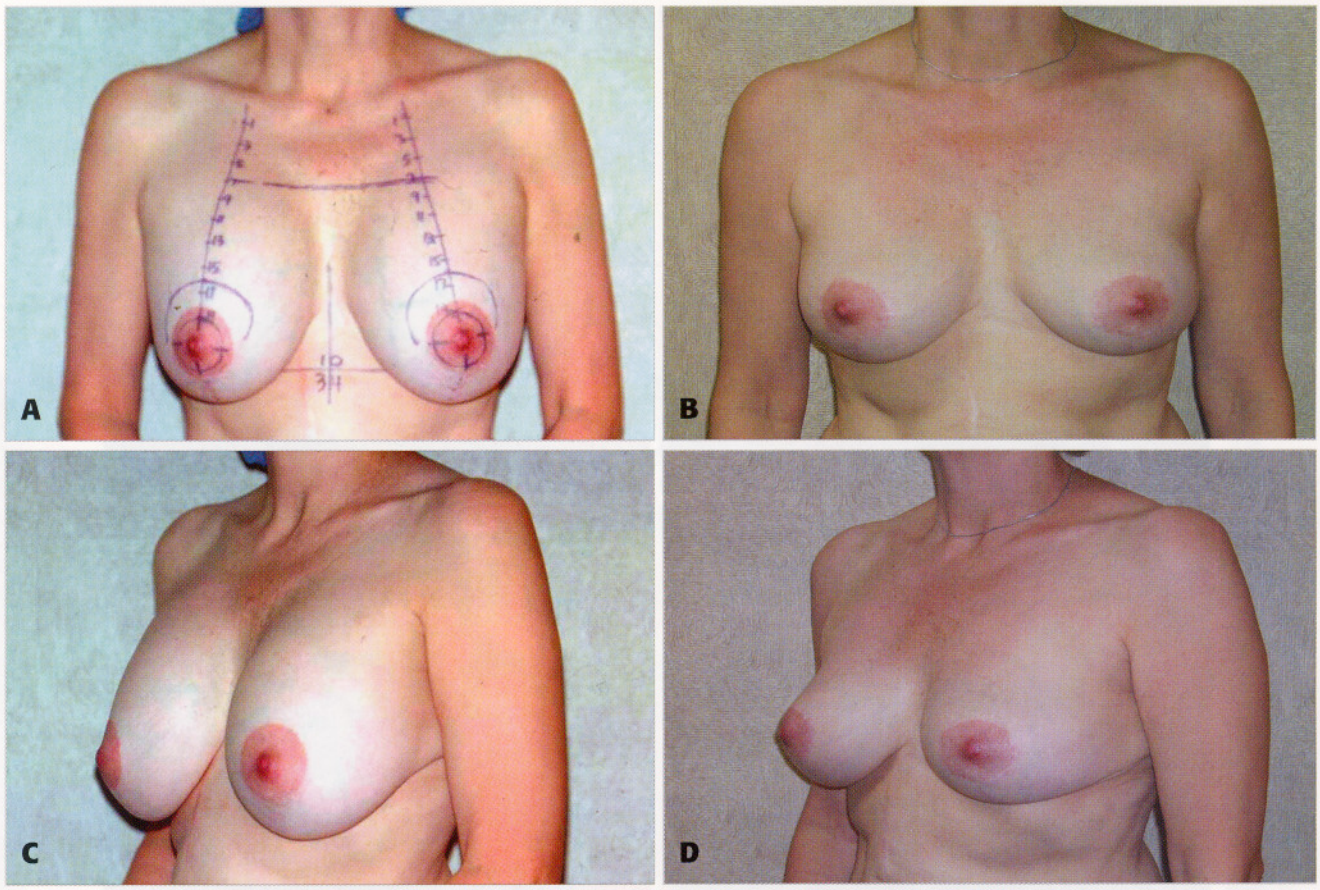

Figure 4. A, C, Preoperative views of a 53-year-old woman with glandular ptosis over old 370-cc silicone gel-filled implants. **B, D,** Postoperative views 22 months after explantation, capsulectomy, and helium balloon mastopexy.

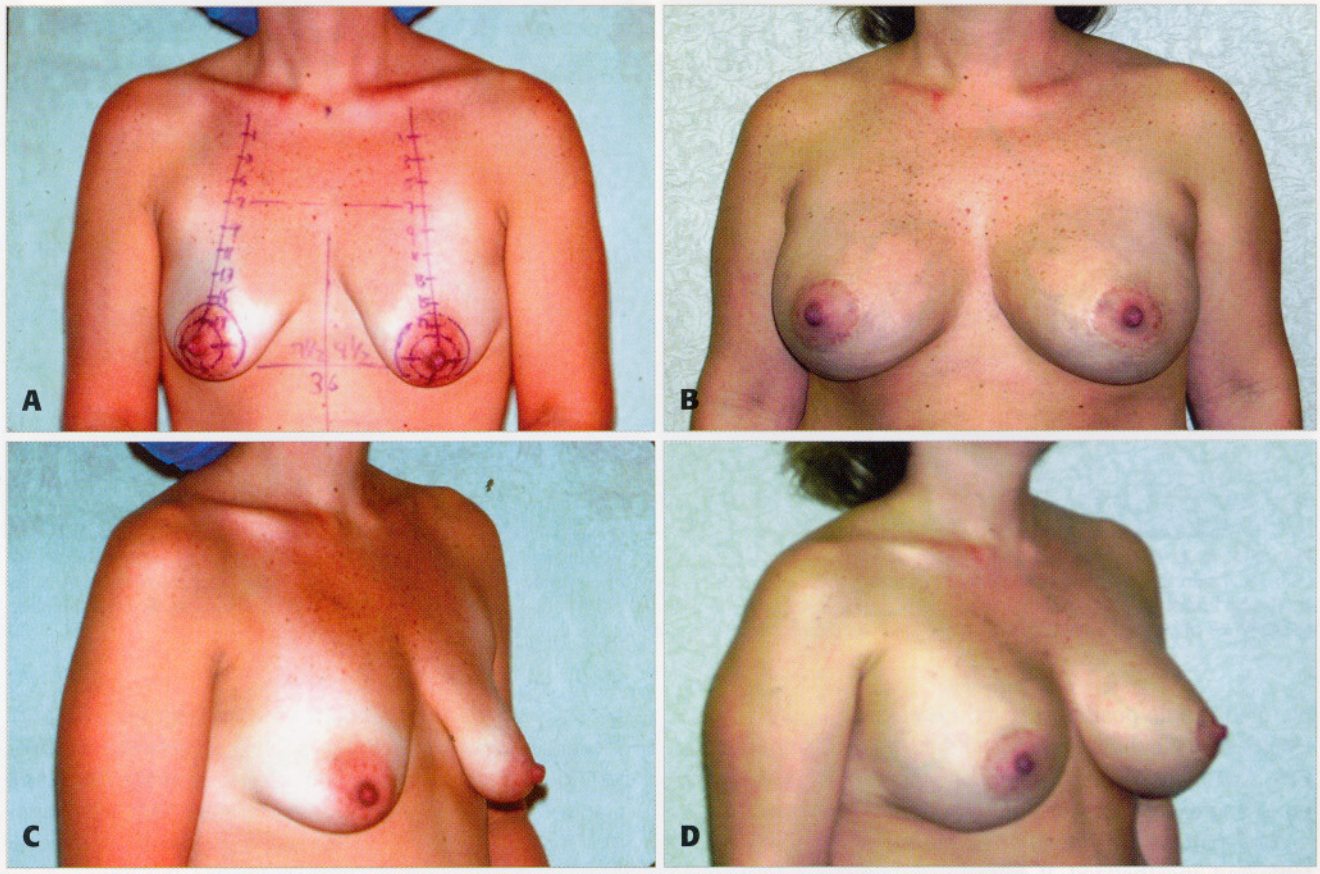

Figure 5. A, C, Preoperative views of a 35-year-old woman with breast atrophy and ptosis after 2 pregnancies and 60-pound weight loss. **B, D,** Postoperative views 2.5 years after submuscular augmentation with 450-cc silicone gel-filled implants and helium balloon mastopexy.

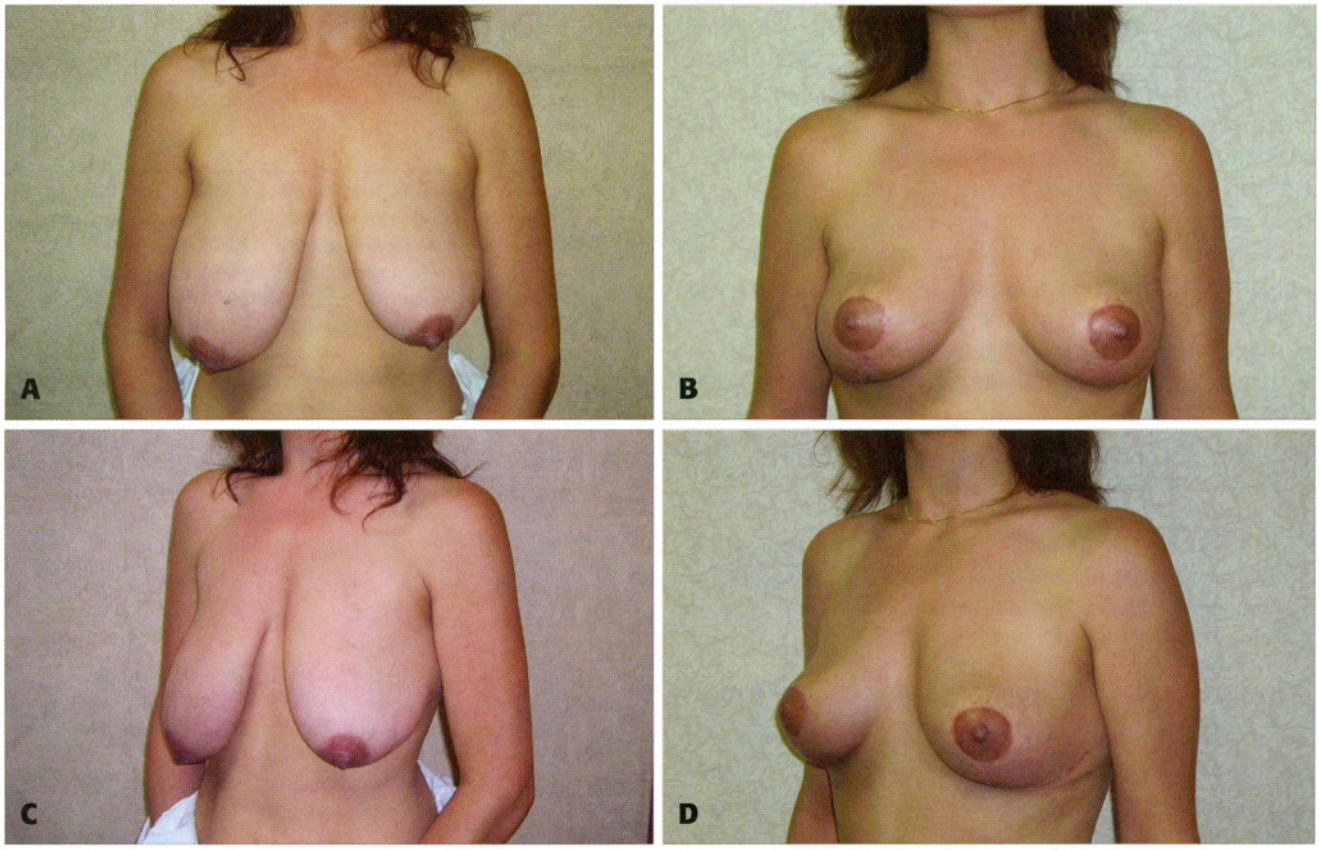

Figure 6. A, C, Preoperative views of a 42-year-old woman with bilateral breast enlargement and severe ptosis. **B, D,** Postoperative views 6 months following lipoplasty breast reduction (right breast, 400 cc aspirated; left breast, 200 cc aspirated) and helium balloon mastopexy.

length on the 2 sides of the closure some gathering of the longer side would have been necessary. Any pleating of the skin edges resolves spontaneously over a few months' time. The length of the stapled closure depends on the degree of skin redundancy but it is never extended onto the chest wall, always ending by the intersection of the IMF with the anterior axillary line (Figure 3).

Additional staples were placed as needed, drawing in progressively more skin until the breast had the desired shape, or even somewhat exaggerated lower pole tightness, as judged with the patient alternately supine and upright. A snug closure is desirable to minimize late "bottoming out." The bulk of the redundant skin within the stapled closure provided a safety barrier to an excessively tight final closure: if the skin edges could be approximated by staples with the extra skin in place they could be sutured without undue tension once the skin was resected. The curvilinear closure without skin undermining also minimizes the risks of ischemia and dehiscence.

If the originally planned position of the nipple/areola did not look right at this time, its location can be adjusted, although this necessitated removal and replacement of some of the staples. When each breast had an excellent shape and there was good symmetry between them, the adjacent edges of the stapled skin were marked with surgical ink and a few crosshatches were marked to assist in alignment during closure. The staples were removed, leaving an outline of the excess skin. Reliance on the position of the crosshatches when closing the wound is recommended because realignment at this time may change the shape the breast had when it was stapled.

The redundant skin was excised, sparing the nipple/areola. The areola was elevated to its new position with a stitch from its 12 o'clock position to the breast meridian line at the top of the new areolar window and all incisions were closed with inverted 3-0 absorbable suture (Monocryl; Ethicon, Somerville NJ). The closure was supported by wound closure strips (Suture Strips Plus; Derma Sciences, Princeton NJ).

If augmentation was to be performed simultaneously with mastopexy the implant was inserted first through an oblique incision within the skin to be discarded during the mastopexy. If there was any doubt as to whether a mastopexy would be required the implant was inserted through a periareolar or other approach. When it was determined that the implants are symmetrically positioned the mastopexy was performed as described above. It is important to press gently downward on the implant as the staples are being placed to avoid making the closure so snug as to force the implant upward.

RESULTS

Seventy-two patients underwent mastopexy (14), mastopexy/augmentation (52), or implant removal/

replacement with mastopexy (6) over a 3-year period ending March 31, 2007 (Figures 4 and 5). Nine patients (12.5%) required reoperation, either for implant malposition (2), residual/recurrent ptosis (3), or for both indications (4). Two patients (2.8%) required scar revision. All implants in patients undergoing primary augmentation were placed in a totally submuscular position. Although this resulted in a greater incidence of superior implant malposition, it provided greater long-term support for the weight of the implant, particularly in patients requesting larger cup sizes. There were no instances of infection, hematoma, or skin/nipple/areola necrosis, although the 8 patients who smoked cigarettes were advised of a higher risk of such problems. These numbers can be compared to others in the literature.[18,21] The procedure has more recently been used with good results in 2 patients undergoing breast reduction by lipoplasty (Figure 6). As opposed to traditional methods of breast reduction, this combination does not require development of a specific pedicle for the nipple/areola.

DISCUSSION

The helium balloon mastopexy allows precise tailoring of the redundant breast skin. This is especially helpful after insertion of an implant, solving the problem of simultaneous enlargement of the breast and tightening of its skin envelope. Although the scar in the lower, outer quadrant of the breast is longer than it would be in a purely vertical direction, the added length allows the redundant skin to be addressed without extending the scar below the inframammary fold or onto the lateral chest wall. Scars in the lower, outer quadrant of the breast usually heal very well and oblique incision placement also eliminates the T junction scar at the IMF of the inverted-T technique.

The helium balloon mastopexy as described in this paper is a "skin only" procedure. While this may arguably lead to a greater incidence of recurrent ptosis,[22, 23] treatment of recurrence is so straightforward, essentially involving only the resection of additional skin in the lower outer quadrant of the breast, that the safety outweighs any disadvantages, particularly for the less experienced surgeon. Because there is less disruption of the breast parenchyma than in more invasive techniques, mastopexy in the previously augmented breast and augmentation/implant revision in the previously lifted breast also involve less risk.

CONCLUSION

Mastopexy and augmentation/mastopexy can be performed with predictably good results and minimal risk of serious complication by following the principles outlined for the helium balloon technique. ◗

ACKNOWLEDGMENTS

The authors are grateful to Rosanne Valentino, RN; Dennis O'Leary, CRNA; Twila Hancock; and Kathy Meter-Mahler for their help with the development of this technique and care of patients.

DISCLOSURES

The authors have no financial interest in and receive no compensation from manufacturers of products mentioned in this article.

REFERENCES

1. Rohrich RJ, Thornton JF, Jakubietz RG, Jakubietz MG, Grünert JG. The limited scar mastopexy: current concepts and approaches to correct breast ptosis. *Plast Reconstr Surg* 2004; 114:1622-1630.
2. Meyer R, Kesselring U. Reduction mammaplasty with an L-shaped suture line. *Plast Reconstr Surg* 1975; 55:139-148.
3. Regnault P. Breast reduction: B technique. *Plast Reconstr Surg* 1980; 65:840-845.
4. Marchac D, de Olarte G. Reduction mammaplasty and correction of ptosis with a short inframammary scar. *Plast Reconstr Surg* 1982; 69:45-55.
5. DeLongis, E. Mammoplasty with an L-shaped limited scar and retropectoral dermopexy. *Aesthetic Plast Surg* 1986; 10:171-175.
6. Bozola AR. Breast reduction with short L scar. *Plast Reconstr Surg* 1990; 85:728-738.
7. Chiari A Jr. The L short-scar mammaplasty: A new approach. *Plast Reconstr Surg* 1992; 90:233-246.
8. Chiari A Jr. The L short-scar mammaplasty: 12 years later. *Plast Reconstr Surg* 2001; 108:489-495.
9. Pallua N, Ermisch C. I becomes L: Modification of the vertical mammaplasty. *Plast Reconstr Surg* 2003; 111:1860-1870.
10. Spear SL, Howard MA. Evolution of the vertical reduction mammaplasty. *Plast Reconstr Surg* 2003; 112:855-868.
11. Strömbeck JO. Mammaplasty: Report of a new technique based on the two-pedicle procedure. *Brit J Plast Surg* 1960; 13:79-90.
12. Dufourmentel C, Mouly R. Plastie mammaire par la méthode oblique [Mammaplasty by the oblique method]. *Ann Chir Plast* 1961; 6:45-58.
13. Spear S. Augmentation/mastopexy: "Surgeon, beware." *Plast Reconstr Surg* 2003; 112:905-906.
14. Haeck P. Combining augmentation and mastopexy: Double the trouble? *Plast Surg News* 2004; June:18.
15. Spear S, Giese S. Simultaneous breast augmentation and mastopexy. *Aesth Surg J* 2002; 20: 155-165.
16. Handel N. Secondary mastopexy in the augmented patient: A recipe for disaster. *Plast Reconstr Surg* 2006; 118(7S):152S-163S.
17. Gorney M. Ten years' experience in aesthetic surgery malpractice claims. *Aesth Surg J* 2001; 21:569-571.
18. Stevens WG, Stoker DA, Freeman ME, Quardt SM, Hirsch EM, Cohen R. Is one-stage breast augmentation with mastopexy safe and effective? A review of 186 primary cases. *Aesth Surg J* 2006; 26:674-681.
19. Whidden P. The tailor-tack mastopexy. *Plast Reconstr Surg* 1978; 62:347-354.
20. Regnault P. Breast ptosis: Definition and treatment. *Clin Plast Surg* 1976; 3:193-203.
21. Spear SL, Low M, Ducic I. Revision augmentation mastopexy: Indications, operations, and outcomes. *Ann Plast Surg* 2003; 51:540-546.
22. Graf R, Biggs TM. In search of better shape in mastopexy and reduction mammoplasty. *Plast Reconstr Surg* 2002; 110:309-317.
23. de la Plaza R, de la Cruz L, Moreno C. Mastopexy utilizing a dermoglandular hammock flap. *Aesth Surg J* 2005; 25:31-36.

Accepted for publication November 15, 2007.

Reprint requests: Edward A. Pechter, MD, 25880 Tournament Road, Suite 217, Valencia CA 91355-2840.

1090-820X/$34.00

doi:10.1016/j.asj.2008.03.002